

QUANTITATIVE PERFUSION ASSESSMENT DURING FLUORESCENCE ANGIOGRAPHY



Anna J. Lytchakov, BA;¹ John Dalloul, MS, BS;¹ Ashley C. Dodd, MD, MS;¹ Micah Holloway, MD;¹ Alison J. Lehane, MD, MPH;¹ Edward M. Gong, MD;^{2,3} Timothy B. Lautz, MD;^{1,4} Seth D. Goldstein, MD, MPhil^{1,4}

1. Department of Surgery, Ann & Robert H. Lurie Children's Hospital, Chicago, IL

2. Division of Urology, Ann & Robert H. Lurie Children's Hospital, Chicago, IL

3. Department of Urology, Northwestern University Feinberg School of Medicine, Chicago, IL

4. Division of Pediatric Surgery, Department of Surgery, Northwestern University Feinberg School of Medicine, Chicago, IL

Introduction

Accurate intraoperative assessment of anatomic structures and tissue perfusion is critical in pediatric surgery, where smaller, more delicate anatomy and limited physiologic reserve can increase operative complexity. Traditional assessment is largely subjective, relying primarily on surgeon visualization and tactile feedback.

Indocyanine Green (ICG) is a well-established fluorophore that enables real-time visualization of anatomy and tissue perfusion when coupled with a near-infrared camera system. However, fluorescence interpretation is still largely subjective and dependent on surgeon assessment of fluorescence signal intensity.

More recently, commercially available quantitative fluorescence analysis platforms have enabled real-time, measurement of fluorescence signal. Its application in pediatric surgery has not yet been characterized.

Methods

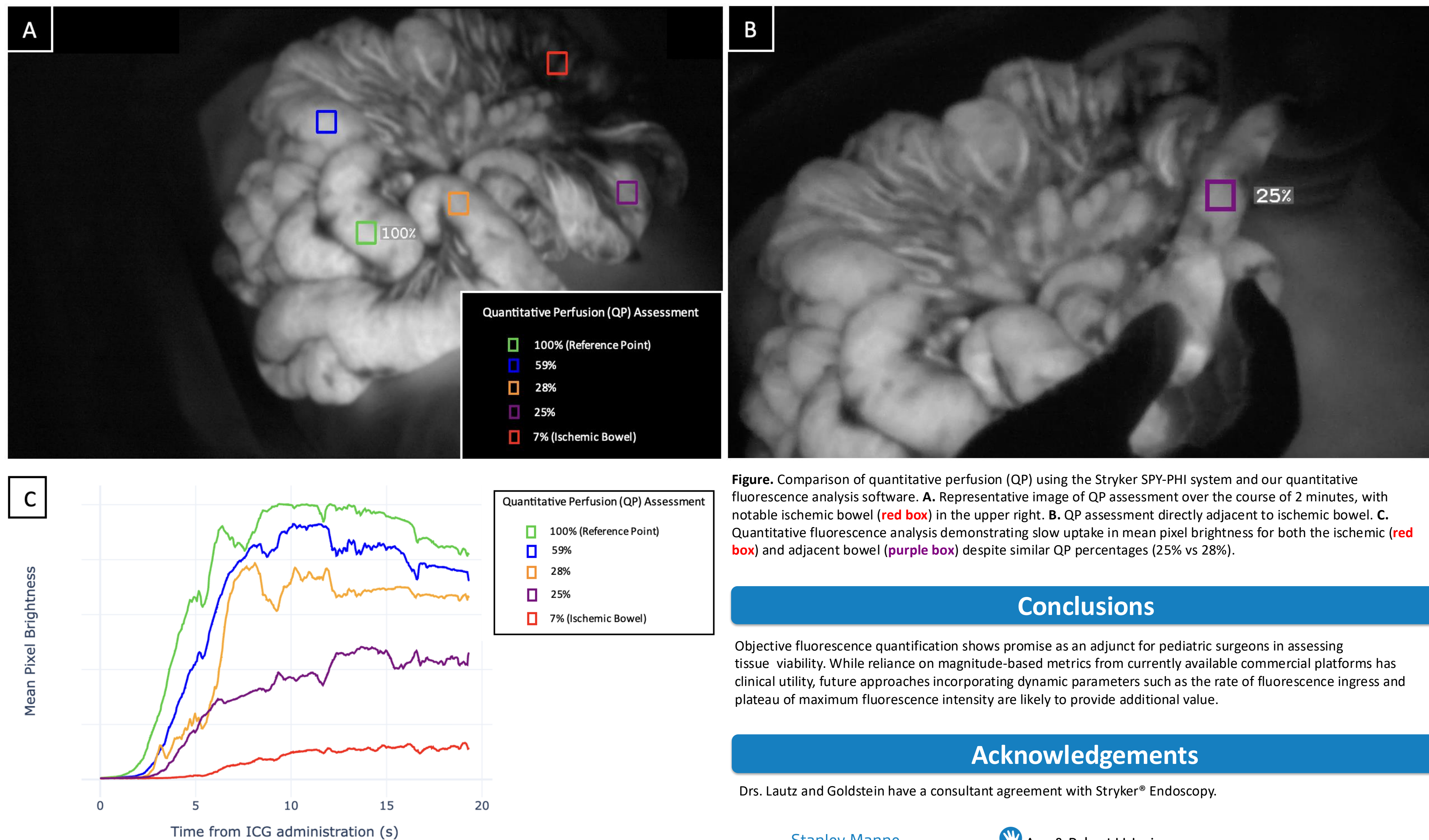
Using the Stryker® 1788 imaging tower incorporating the **Quantitative Perfusion (QP)** function, a series of intraoperative pediatric cases involving either testicular torsion or intestinal resection in the setting of ischemia were evaluated. QP-derived perfusion metrics were then compared with surgeon intraoperative judgement and with full computer-automated, segmented quantitative fluorescence analysis.

Computer-automated analysis consisted of video review using a previously developed Python program to generate high-temporal resolution time-intensity curves. These curves were derived from mean pixel brightness within user-defined polygonal regions of interest (ROIs). Mean brightness was calculated across all frames of the analyzed videos for each specified ROI (boxes in figure).

Results

QP function demonstrated a measurable decrement in plateau fluorescence signal intensity over time that correlated with expert intraoperative surgeon assessment. Similarly, QP function identified decreased fluorescence signal in ischemic tissue compared to healthy baseline tissue with consistent quantitative trends observed across the analyzed regions (ROIs).

Computer-automated analysis confirmed these findings, while also identifying differences in time to maximum intensity and maximum fluorescence plateau between the healthy and ischemic tissue regions. Although QP metrics in tissue adjacent to ischemic areas were similar to those of proximal healthy tissue, computer-automated analysis more clearly delineated these perfusion differences, particularly with respect to time to maximum intensity and fluorescence signal.



Conclusions

Objective fluorescence quantification shows promise as an adjunct for pediatric surgeons in assessing tissue viability. While reliance on magnitude-based metrics from currently available commercial platforms has clinical utility, future approaches incorporating dynamic parameters such as the rate of fluorescence ingress and plateau of maximum fluorescence intensity are likely to provide additional value.

Acknowledgements

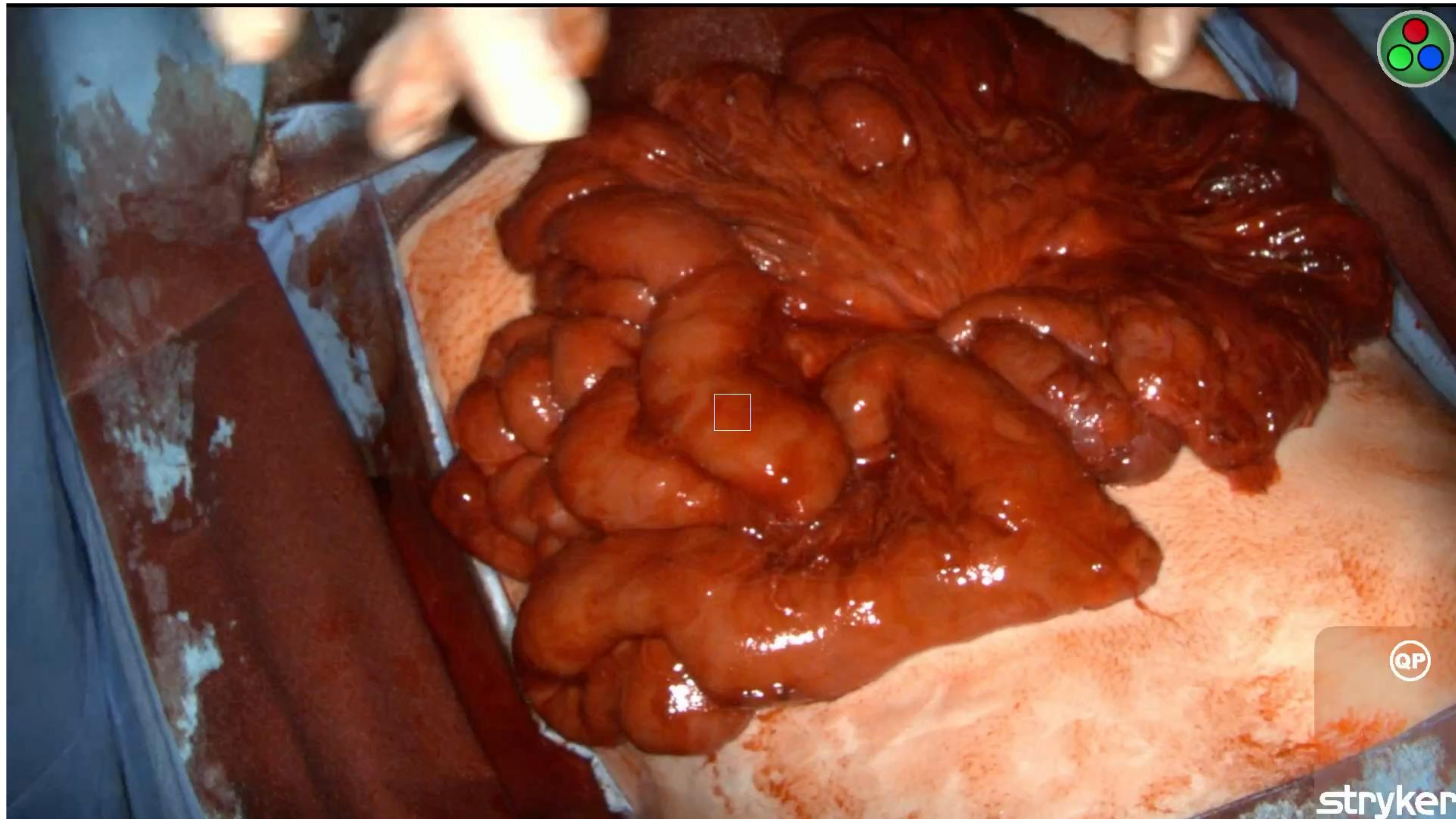Drs. Lautz and Goldstein have a consultant agreement with Stryker® Endoscopy.

Stanley Manne
Children's Research Institute™

Ann & Robert H. Lurie
Children's Hospital of Chicago®

Northwestern Medicine®
Feinberg School of Medicine

Quantitative Perfusion Assessment During Fluorescence Angiography: Bowel Perfusion



Quantitative Perfusion Assessment During Fluorescence Angiography: Testicular Torsion

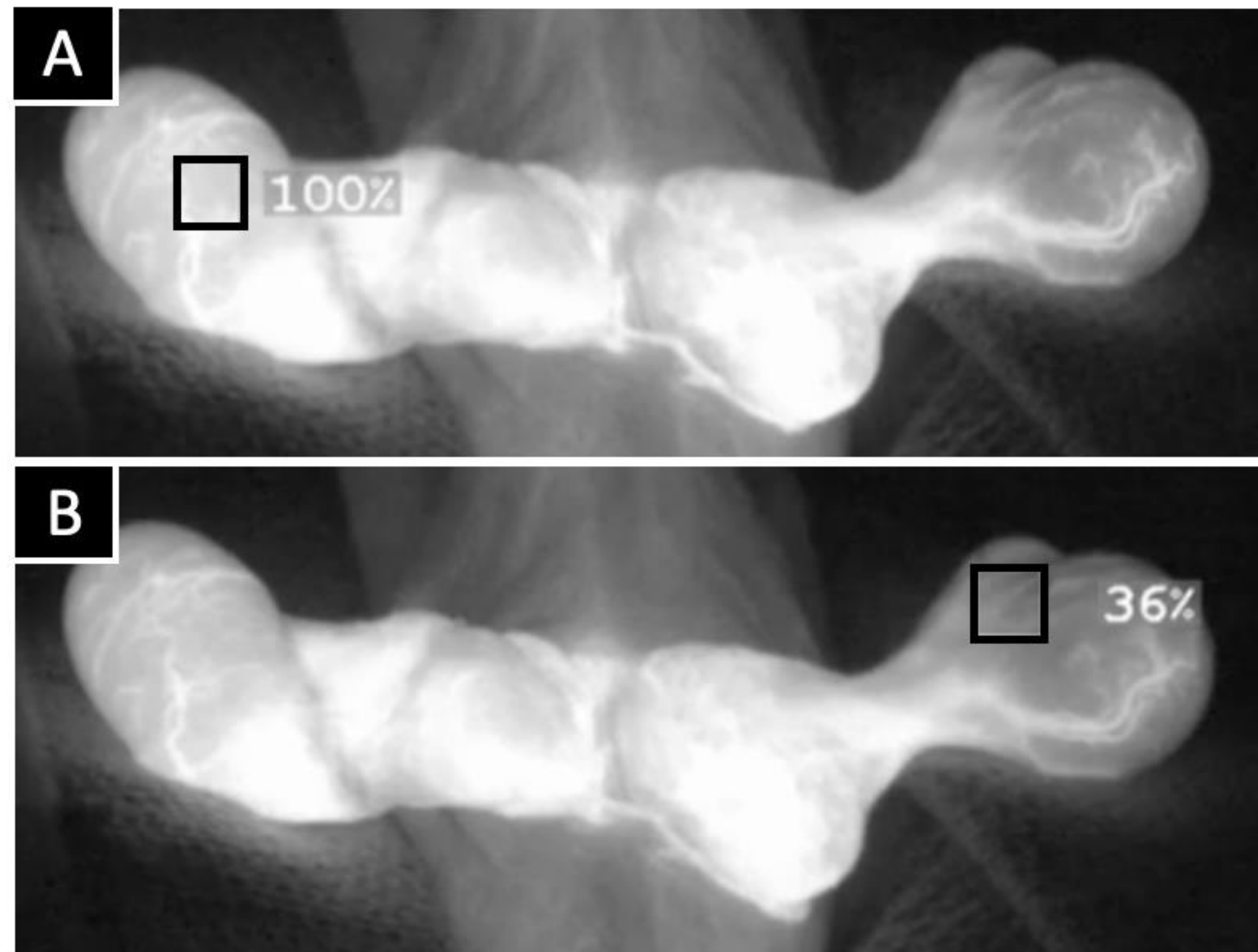



Figure. Quantitative Perfusion (QP) assessment following testicular torsion of the left testicle (screen right). **A.** Maximum intensity and setting of baseline (100%) in the contralateral healthy tissue. **B.** QP comparison of affected tissue approximately 20 seconds after baseline set.

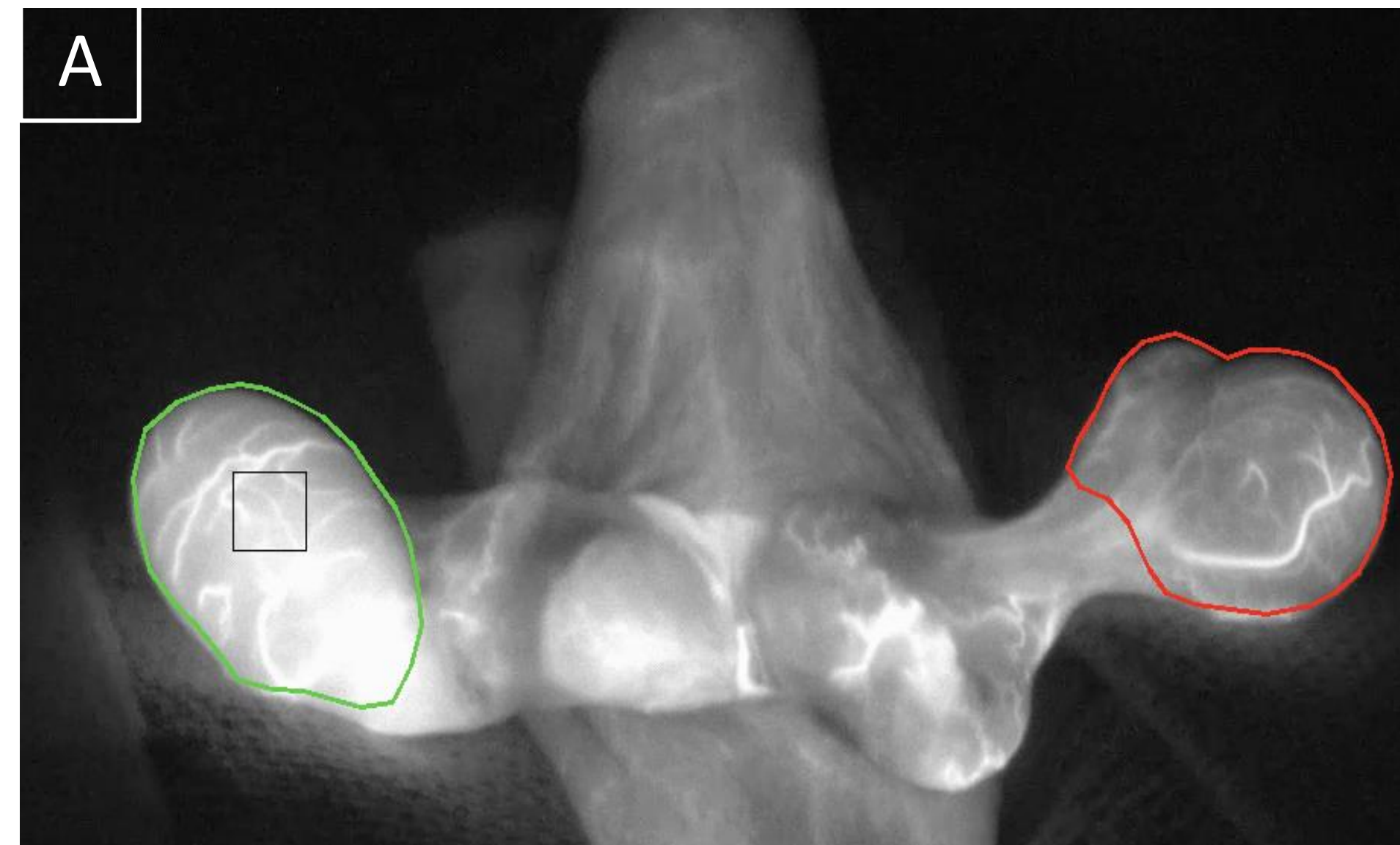


Video: Quantitative Perfusion (QP) assessment following testicular torsion of the left testicle (screen right).

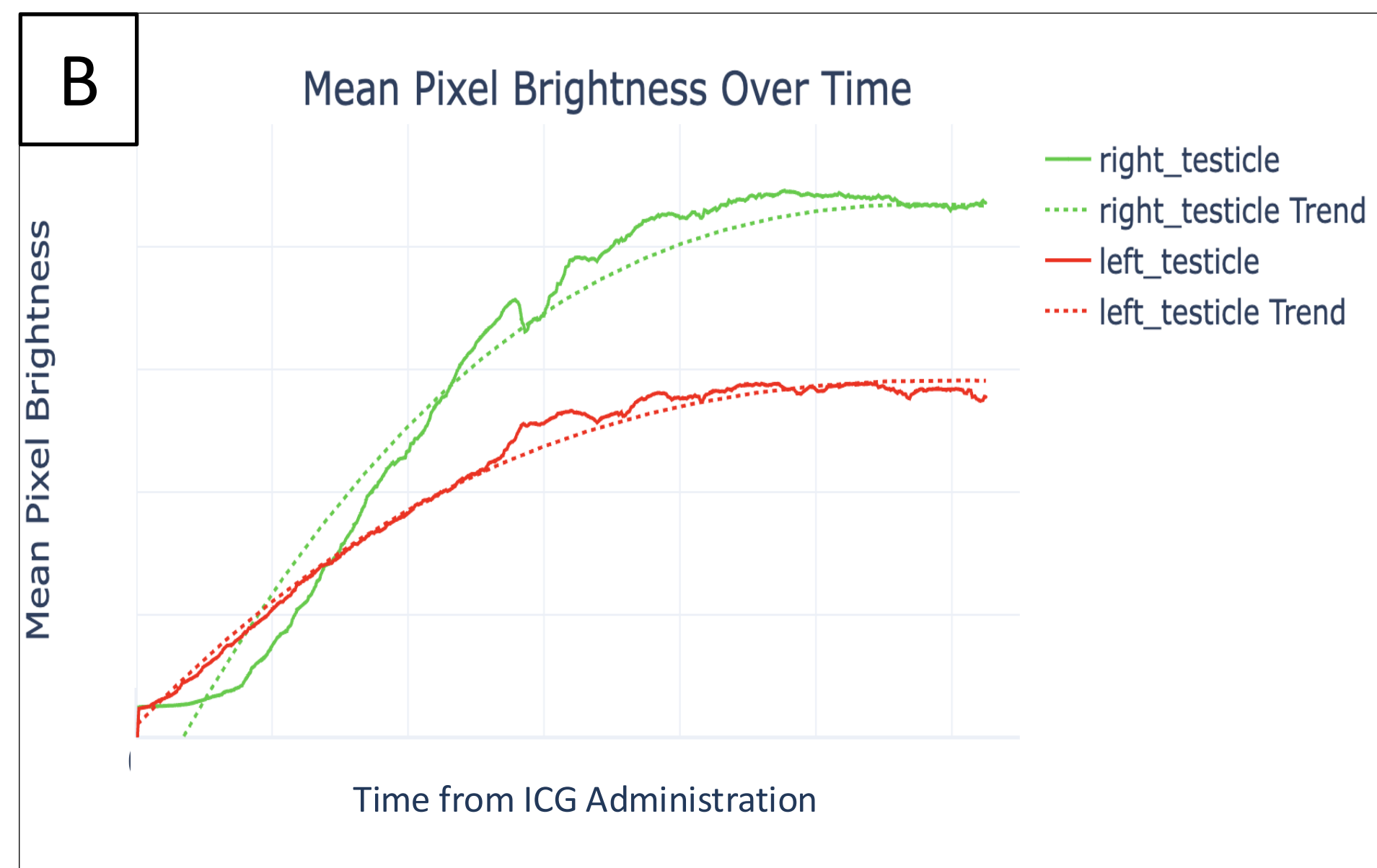
Quantitative Perfusion Assessment During Fluorescence Angiography: Testicular Torsion



A. Intraoperative comparison of signal intensity between healthy testis and a recently detorsed testis (figure right) using QP.



B. Magnitude of fluorescent signal intensity over time following ICG infusion between the healthy (**green**) and recently detorsed (**red**) testis.



Quantitative Perfusion Assessment During Fluorescence Angiography: Ovarian Torsion

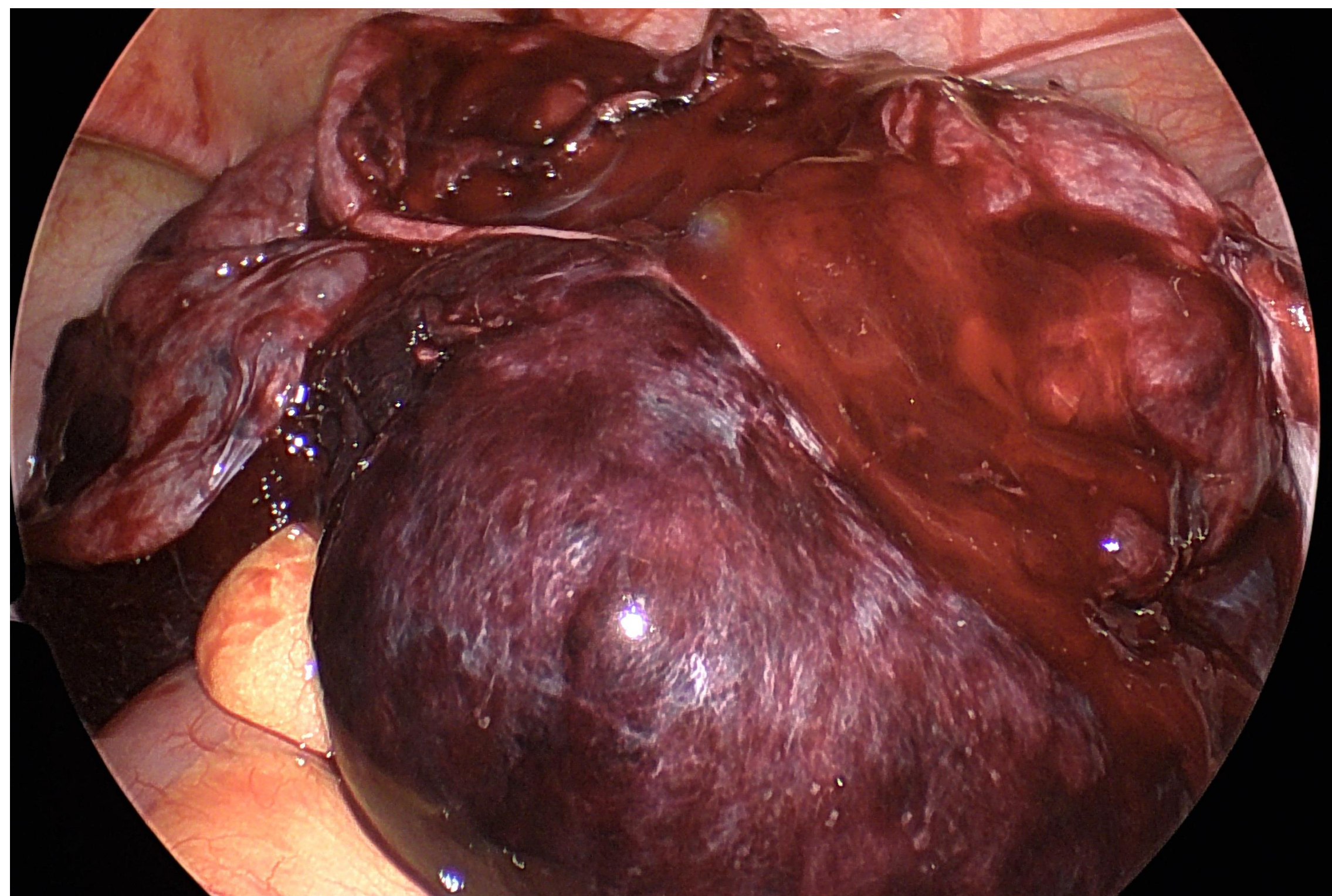
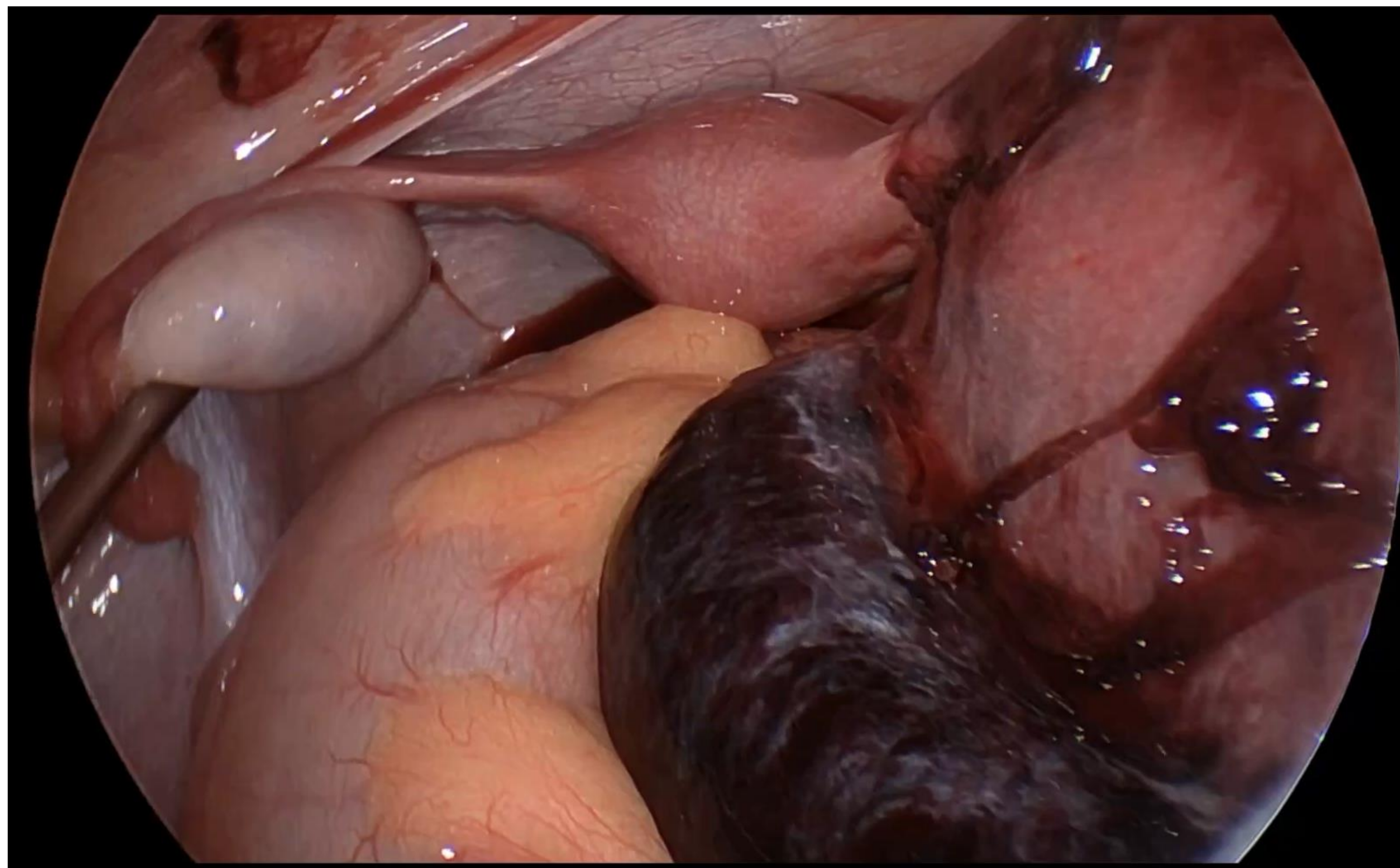


Figure. 9 year old female with two days of right lower quadrant pain and ultrasound with large 8.2cm ovarian lesion with evidence of ovarian torsion. In the OR, evidence of ovarian necrosis on the right.



Video. Fluorescent angiogram detects flow in tube, but not the ovary

ICG Fluorescence as a Surrogate for Biliary Drainage Following Kasai



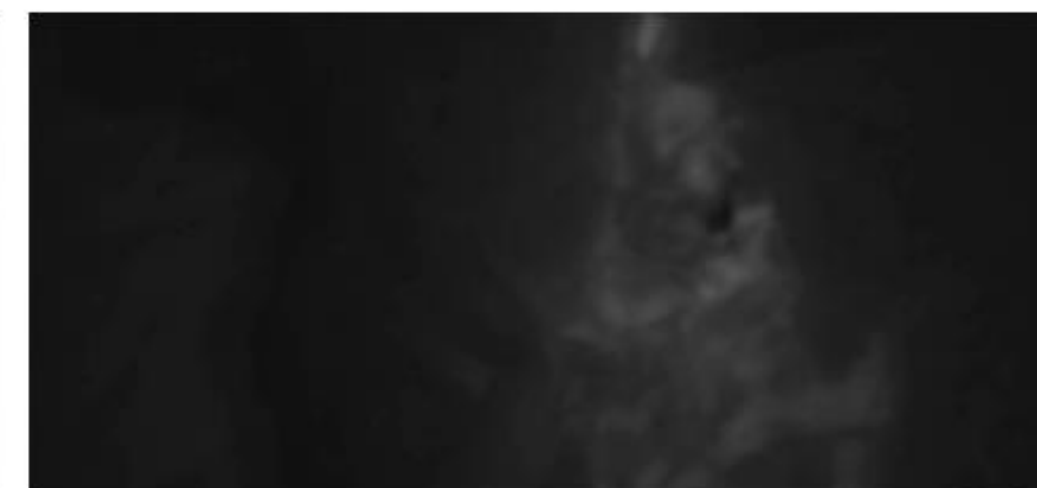
Grade 0

No fluorescent signal present



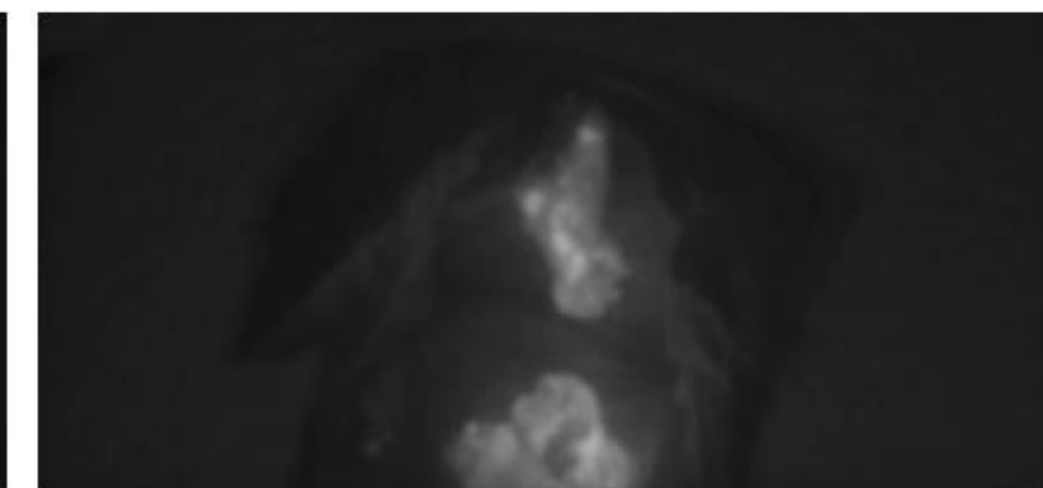
Grade I

Speckled foci of fluorescent signal; "starry sky" appearance



Grade II

fluorescence present, with islands of higher signal intensity in some areas



Grade III

Diffuse fluorescence present, with high signal intensity throughout